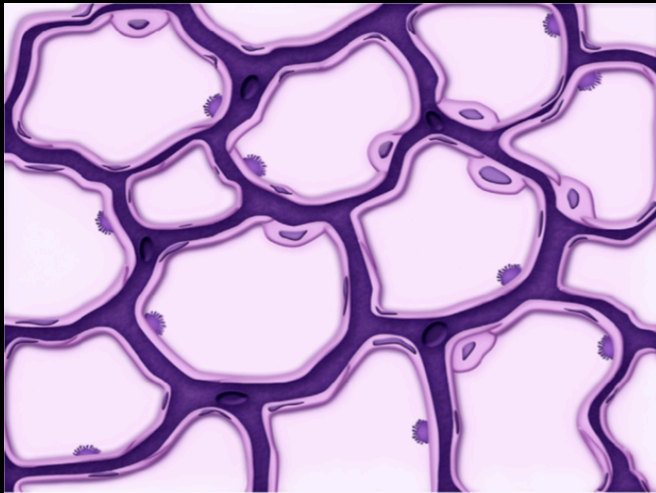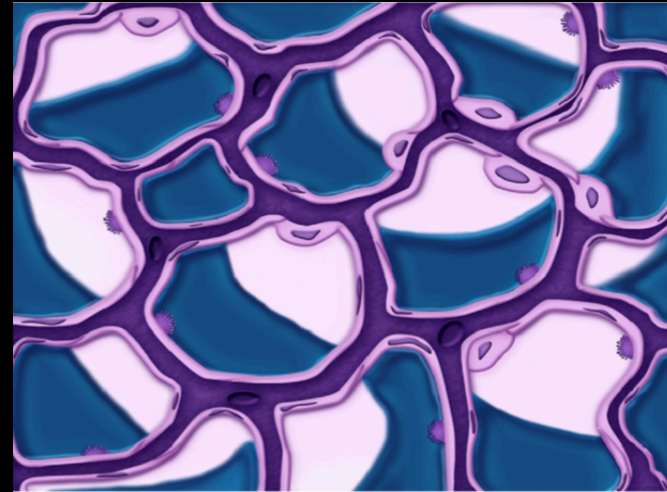


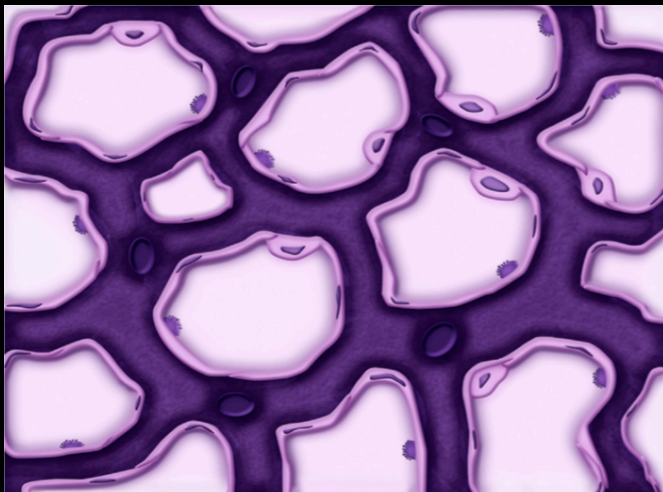
A

Normal alveoli



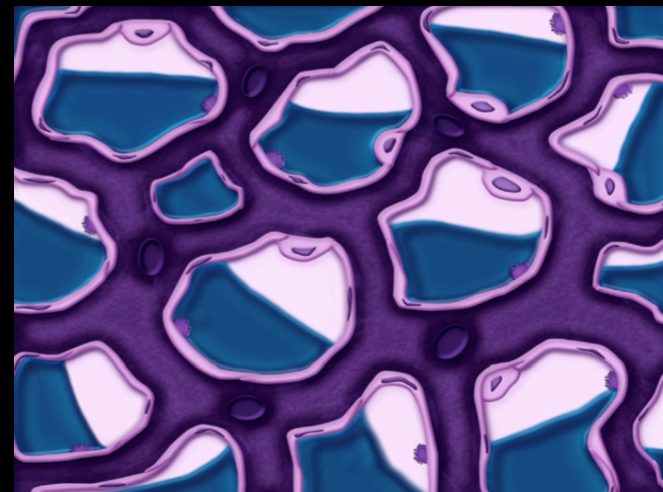
B

Abnormal alveolar space



C

Abnormal interstitium

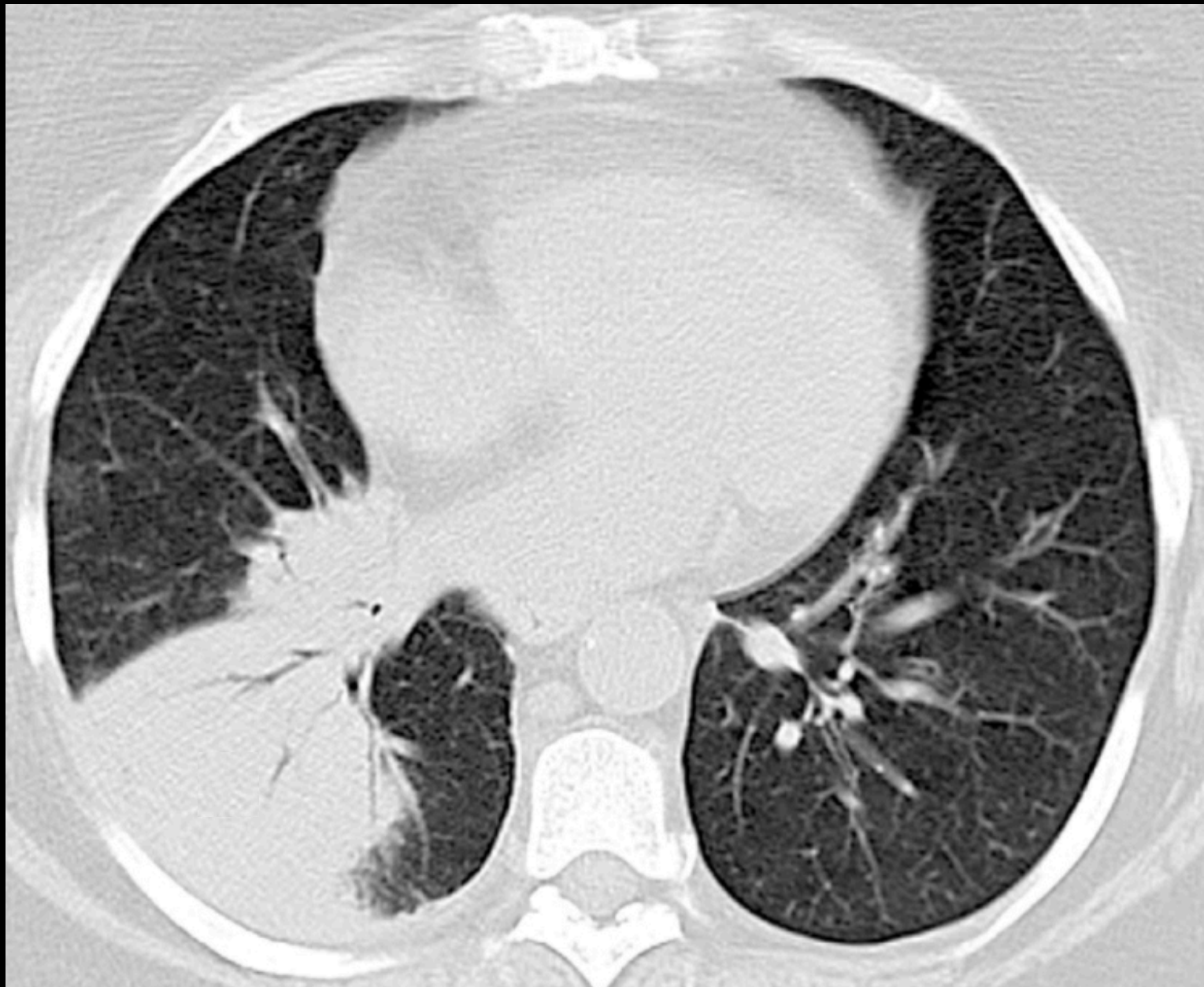


D

Abnormal alveolar space
and interstitium

CONSOLIDATION

- Consolidation appears as a homogeneous increase in pulmonary parenchymal attenuation that obscures the margins of vessels and airway walls.
- An air bronchogram may be present.



TRACTION BRONCHIECTASIS

- Irregular bronchial and bronchiolar dilatation caused by surrounding retractile pulmonary fibrosis